CASE REPORT

Skeletal Open-Bite Correction with Mini-Implant Anchorage and Minimally Invasive Surgery

FLAVIO URIBE, DDS, MDS
NILOUFAR AZAMI, DDS
DEREK STEINBACHER, DMD, MD
NANDAKUMAR JANAKIRAMAN, BDS, MDS, MDentSc
RAVINDRA NANDA, BDS, MS, PhD

Temporary anchorage devices (TADs) have expanded the boundaries of tooth movement in three dimensions, increasing the scope of potential orthodontic corrections.[1,2] The primary uses for TADs include molar intrusion, molar protraction, distalization of posterior teeth, and anchorage for patients with missing teeth.[3] In addition, numerous reports have documented the successful treatment of mild to moderate surgical cases, obviating the need for orthognathic surgery.[4-6]


Dr. Uribe


Dr. Azami


Dr. Steinbacher


Dr. Janakiraman


Dr. Nanda

Dr. Uribe is an Associate Professor, Postgraduate Program Director, and Charles J. Burstone Endowed Professor, Division of Orthodontics, Department of Craniofacial Sciences; Dr. Azami is a resident, Department of Craniofacial Sciences; and Dr. Nanda is a Professor, Division of Orthodontics, Department of Craniofacial Sciences, University of Connecticut School of Dental Medicine, Farmington, CT. Dr. Steinbacher is an Associate Professor of Plastic Surgery, Assistant Professor of Pediatrics, and Director of Dental Services, Oral Maxillofacial and Craniofacial Surgery, Yale School of Medicine, New Haven, CT. Dr. Janakiraman was formerly with the Department of Orthodontics, University of Louisville, Louisville, KY, and is currently an Assistant Professor, Georgia School of Orthodontics, Atlanta, GA; email: nduggu@hotmail.com. Dr. Nanda is also an Associate Editor and Dr. Uribe is a Contributing Editor of the *Journal of Clinical Orthodontics*.

Fig. 1 24-year-old female patient with anterior open bite and missing lower teeth before treatment.

Kuroda and colleagues demonstrated the correction of skeletal anterior open bites with posterior intrusion using mini-implants.[5] Similar reports have described management of the vertical dimension by means of molar intrusion with TADs.[7-9] In a patient with a long face and retrognathic mandible, maxillary posterior intrusion not only reduces the mandibular plane angle by mandibular autorotation, but also diminishes chin projection, thus improving facial esthetics and mimicking the results achieved through orthognathic surgery.[6] On the other hand, a patient with adequate or slightly excessive chin projection and a long face may be unfavorably affected by this mandibular autorotation.

The present article describes the management of a complex skeletal open bite by a combination of miniscrew-anchored maxillary posterior intrusion and minimally invasive surgery.

Diagnosis and Treatment Planning

A 24-year-old female patient presented with the chief complaint of anterior open bite (Fig. 1). She had an orthognathic facial profile with excessive lower facial height. In smiling, she showed a reverse smile arc and a 5mm gingival display in the premolar and molar regions. Wide buccal corridors resulted from excessive lingual inclination of the upper posterior segments and constriction of the maxillary arch. The patient had two maxillary occlusal planes, with a step in the canine region and a canted occlusal plane that was lower on the right side. She exhibited a 6mm open bite from canine to canine, a Class II canine relationship, a Class I molar relationship, and a 4mm overjet, as well as a 2mm midline deviation in the lower arch and moderate crowding in the upper arch. The patient was missing the lower right second premolar and left first molar and had porcelain-fused-to-metal crowns on the lower incisors.

Cephalometric analysis confirmed a skeletal Class I relationship (Table 1). Vertically, the mandibular plane and gonial angles were excessive. The maxilla was rotated counterclockwise, and the

TABLE 1
CEPHALOMETRIC ANALYSIS

Measurement	Mean ± S.D.	Pretreatment	Post-Treatment	Difference
SNA	82.0° ± 3.5°	80.0°	79.4°	−0.6°
SNB	80.0° ± 3.4°	79.5°	79.9°	0.4°
ANB	1.6° ± 1.5°	0.4°	−0.5°	−0.9°
Wits appraisal	−1.0mm ± 1.0mm	−3.1mm	−4.9mm	−1.8mm
SN-GoGN	32.0° ± 5.2°	38.1°	35.0°	−3.1°
U1-SN	102.0° ± 5.5°	107.3°	103.3°	−4.0°
IMPA	95.0° ± 7.0°	78.7°	78.2°	0.5°
U6-NF	23.0mm ± 1.3mm	25.8mm	23.2mm	−2.6mm
U1-NF	27.5mm ± 1.7mm	28.2mm	29.7mm	1.5mm
L6-MP	32.1mm ± 1.9mm	21.6mm	21.0mm	−0.6mm
L1-MP	40.0mm ± 1.8mm	31.2mm	30.8mm	−0.4mm
Upper lip-SNPg	3.0mm ± 1.0mm	2.6mm	2.3mm	−0.3mm
Lower lip-SNPg	2.0mm ± 1.0mm	1.3mm	1.6mm	0.3mm

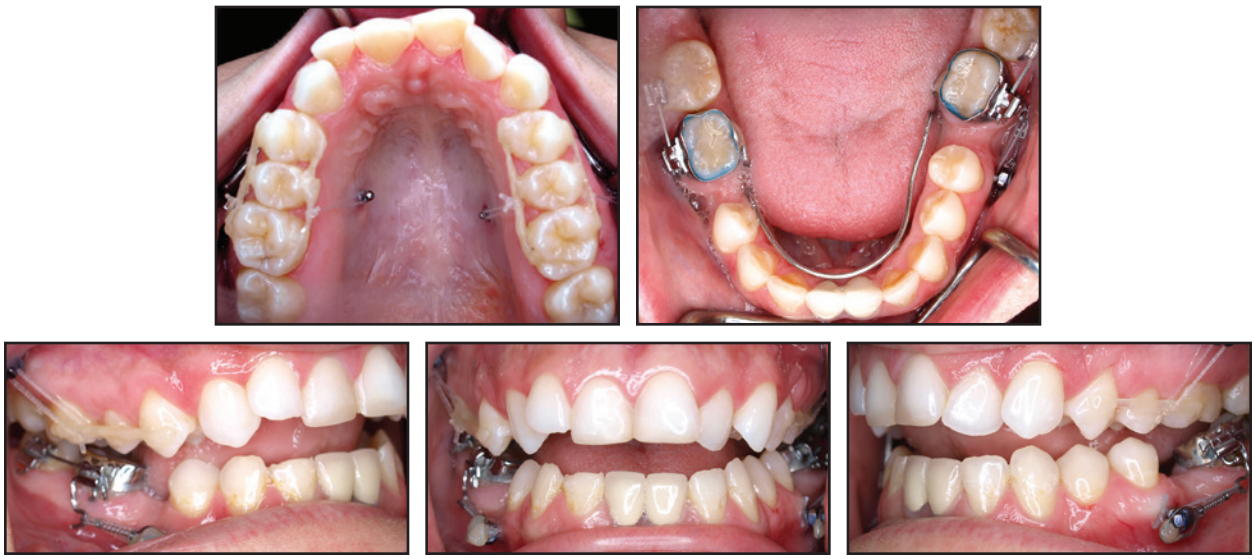

Fig. 2 Two mini-implants* placed in infrazygomatic crest and two in palatal shelves near premolars for posterior intrusion, with fiber-reinforced composite splinting of upper posterior teeth. Two lower mini-implants* placed mesial to edentulous sites for molar protraction with nickel titanium coil springs and lingual arch.**

distance of the upper molar apex to the palatal plane indicated posterior vertical maxillary hyperplasia. Maxillary incisor inclination was normal, but the lower incisors were mildly retroclined.

Treatment objectives were to resolve the anterior open bite, correct the midline deviation and close the edentulous spaces in the lower arch, and reduce the lower facial height while maintaining the orthognathic facial profile.

The first treatment option involved orthodontics combined with orthognathic surgery—a Le Fort I osteotomy for posterior impaction of the maxilla and a bilateral sagittal split osteotomy in the mandible. The second option was to use TADs for intrusion of the upper posterior teeth to level the maxillary occlusion, maintain the incisor display, correct the maxillary cant, and reduce the lower facial height. Both choices would have required either endosseous dental implants or TAD-based protraction of the lower molars to close the edentulous spaces. The patient selected the second treatment option, because it avoided orthognathic surgery, and opted for closure of the lower edentulous spaces with TADs.

Treatment Progress

Two 2mm × 9mm mini-implants* were placed in the infrazygomatic crest, and another two 1.8mm × 8mm mini-implants** were inserted in the palatal shelves near the second premolars (Fig. 2). The upper posterior teeth were splinted by bonding fiber-reinforced composite to the buccal and palatal surfaces of the upper premolars and first molars. Elastic chain between the mini-implants delivered 150g of intrusive force to the posterior dentition both buccally and palatally. In the lower arch, two 2mm × 9mm mini-implants* were placed mesial to the edentulous sites. Power arms were extended from the right first molar and the left second molar, and a protraction force of 150-200g was applied from the mini-implants by nickel titanium coil springs. A lower lingual arch was cemented to lie 3-4mm away from the lingual surfaces of the incisors.

*Mondeal Medical Systems GmbH, Tuttlingen, Germany; www.mondeal.de.
**Imtec, 3M Unitek, Monrovia, CA; www.3Munitek.com.
***Trademark of 3M Unitek, Monrovia, CA; www.3Munitek.com.

Fig. 3 A. Anterior open bite corrected after 36 months of treatment, with slight lateral open bite remaining on left side. B. After 42 months of treatment, showing increased chin prominence due to mandibular autorotation secondary to maxillary molar intrusion.

After eight months of leveling of the maxillary occlusal plane by intrusion of the posterior teeth, preadjusted .022" MBT*** brackets were bonded in both arches and the lower lingual arch was removed. Closure of the edentulous spaces was continued in conjunction with intrusion of the upper molars. The anterior open bite was corrected in 36 months without the use of anterior elastics (Fig. 3). Increased chin prominence due to autorotation of the mandible, secondary to the maxillary posterior intrusion, was observed after 42 months of treatment.

Seven months later, during the finishing stage of treatment, the patient was referred to an oral and maxillofacial surgeon for a reduction genioplasty, in which the chin was repositioned 5mm up and

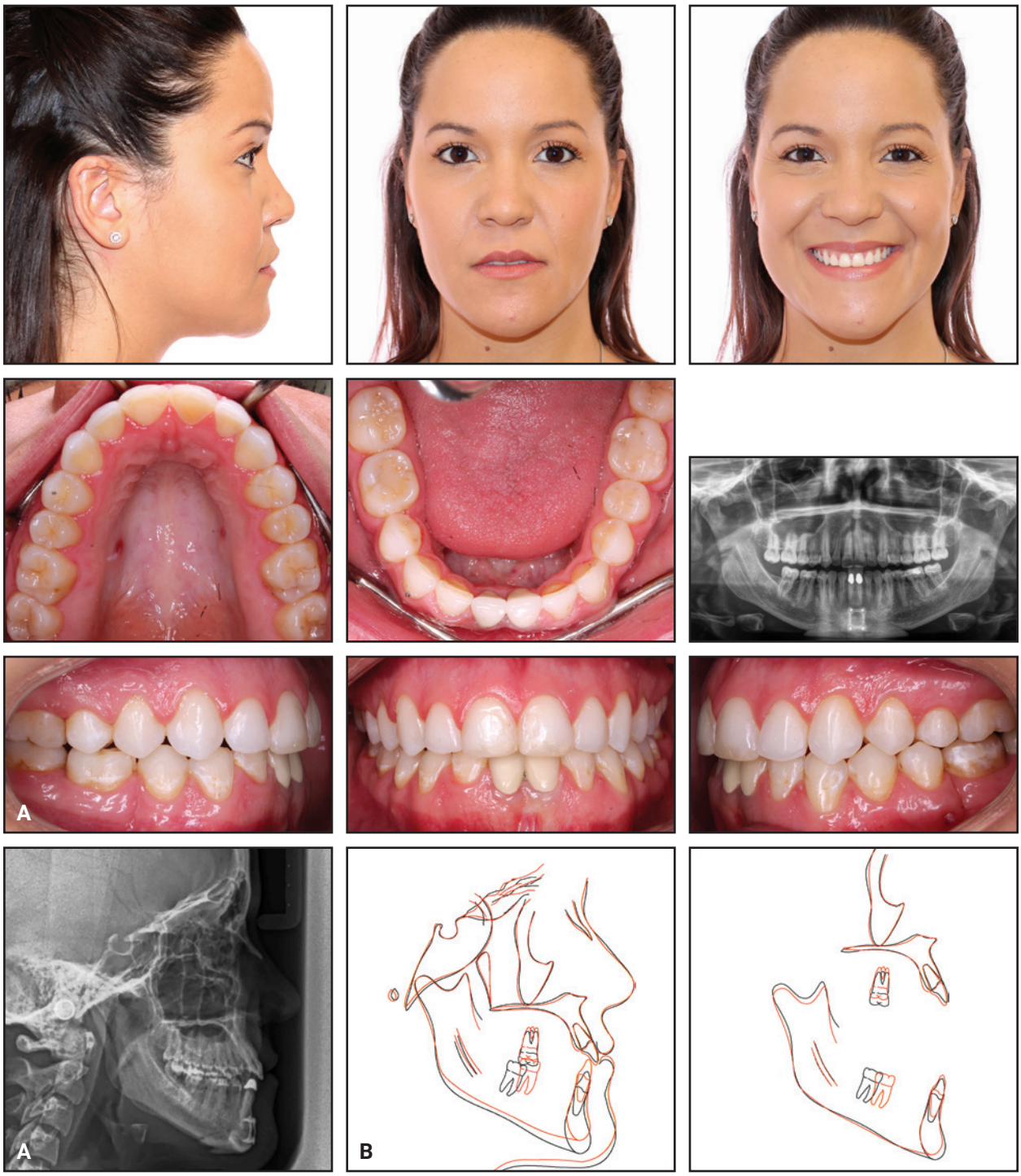

Fig. 4 A. Patient after 53 months of active treatment, including genioplasty and microfat grafting. B. Superimposition of pre- and post-treatment cephalometric tracings.

2mm back. The mentalis muscle and the median raphe were gently thinned to reduce soft-tissue chin thickness. To enhance facial esthetics, submental liposuction was performed by harvesting about 10cc of fat from the abdomen and injecting it into the labiomental crease of the upper lip and the labiomental and nasolabial folds. Finishing was carried out on .016" × .022" beta titanium archwires.

After 53 months of active treatment, Essix† retainers were delivered for retention in both arches. Rigid stainless steel wires were bonded buccally over the lower premolars and molars to prevent space reopening.

Treatment Results

Post-treatment photographs demonstrated a correction of the gingival excess in the maxillary posterior region, a remarkable improvement in the smile arc, and maintenance of the facial profile (Fig. 4). Normal overjet and overbite and a Class I canine relationship were achieved; the molar relationship was Class I on the left side and Class III on the right. The panoramic radiograph showed no evidence of root resorption.

The SNB angle increased slightly, the ANB and mandibular plane angles decreased, and the Wits appraisal decreased as a result of counterclockwise rotation of the mandible after intrusion of the upper posterior teeth (Table 1). The inclination of the lower incisors was maintained as the upper incisors were slightly retracted. The distance from the apex of the upper molars to the nasal floor decreased, and the vertical positions of the lower incisors and molars were maintained.

Cephalometric superimpositions confirmed significant intrusion of the upper molars, counterclockwise rotation of the mandible, and slight extrusion of the upper incisors. Three-dimensional facial superimposition of the treatment changes with color mapping showed that the soft-tissue changes occurred primarily in the chin and the malar region, reflecting the reduction genioplasty and fat-grafting procedures (Fig. 5).

†Registered trademark of Denstply Raintree Essix Glenroe, Sarasota, FL; www.essix.com.

Discussion

The introduction of TADs has led to a paradigm shift in the management of skeletal open bites.[1] Umemori and collegues documented the use of miniplates for the intrusion of lower molars.[9] Other studies demonstrated the intrusion of upper posterior teeth with miniplates placed in the zygomatic buttress.[7,8] Deguchi and collegues inserted mini-implants between the first molars and second premolars or second molars for the correction of skeletal anterior open bite, achieving favorable skeletal changes such as a reduction in the mandibular plane angle and facial convexity.[10] These authors cautioned, however, that their approach might not

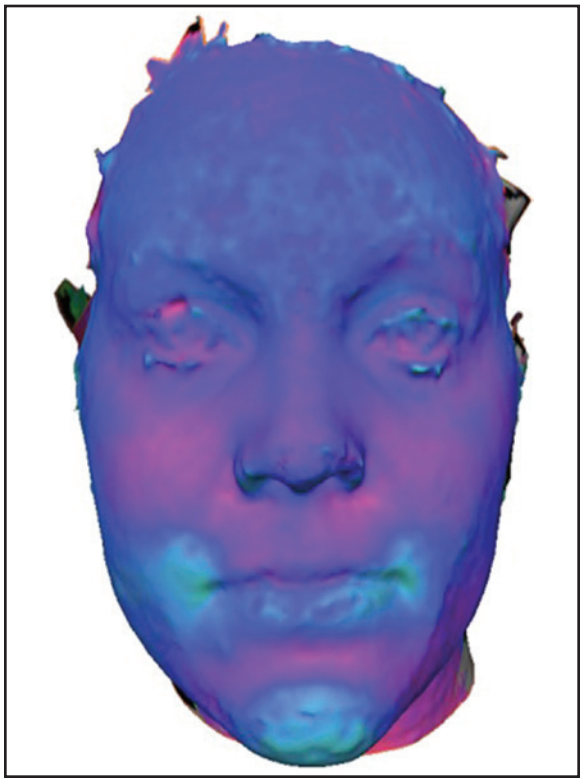

Fig. 5 Three-dimensional color map generated by superimposing images of soft tissues taken just before genioplasty and fat grafting onto images taken nine months after surgery. Reference points are forehead and nasal root. Blue/purple colors indicate minimal change, green (−5mm) indicates volume reduction, and red (5mm) indicates volume increase.

be indicated in cases with Class III facial profiles.

Autorotation of the mandible after molar intrusion is desirable in a Class II patient with a retrognathic profile because it reduces lower anterior facial height, improves the chin projection, reduces facial convexity, and helps increase the overbite. With a Class I or Class III soft-tissue profile, this approach can lead to increased chin prominence and deterioration of the soft-tissue profile. Our patient, who presented with an orthognathic profile, was treated with a vertical reduction genioplasty to reduce lower facial height and achieve posterior repositioning of the chin after upper molar intrusion. Genioplasties have traditionally been used as ancillary procedures to refine the esthetic outcomes of conventional osteotomies,[11] particularly in patients requiring mandibular advancement.[12] Vertical reduction genioplasties have also been employed in conjunction with bimaxillary surgery, showing few complications.[13]

Microfat grafting, which has become popular in the last decade as a method to soften facial wrinkles and improve skin texture,[14] can be used not only as an ancillary procedure in conventional orthognathic surgery, but also as the sole method to address facial hypoplasia of the maxilla and mandible. The esthetic results tend to remain stable in immobile areas such as the chin and malar region (about 15% fat resorption), compared with more mobile areas such as the lips (about 50%).[14] The success of our patient's fat grafting in the infraorbital and perinasal regions was substantiated by color-map superimposition of soft tissues immediately before and nine months after surgery.

ACKNOWLEDGMENT: The authors would like to thank Dr. Yasas Shri Nalaka Jayaratne for performing the 3D soft-tissue superimposition.

REFERENCES

1. Cope, J.B.: Temporary anchorage devices in orthodontics: A paradigm shift, Semin. Orthod. 11:3-9, 2005.
2. Melsen, B.: Northcroft Lecture: How has the spectrum of orthodontics changed over the past decades? J. Orthod. 38:134-143, 2011.
3. Jaiswal, A.K.; Dua, A.K.; Ranganathan, L.K.; Mascarenhas, R.; and Gandhi, S.: Nonsurgical treatment of an adult with severe anterior open bite, J. Clin. Orthod. 45:341-347, 2011.
4. Jing, Y.; Han, X.; Guo, Y.; Li, J.; and Bai, D.: Nonsurgical correction of a Class III malocclusion in an adult by miniscrew-assisted mandibular dentition distalization, Am. J. Orthod. 143:877-887, 2013.
5. Kuroda, S.; Katayama, A.; and Takano-Yamamoto, T.: Severe anterior open-bite case treated using titanium screw anchorage, Angle Orthod. 74:558-567, 2004.
6. Kuroda, S.; Sakai, Y.; Tamamura, N.; Deguchi, T.; and Takano-Yamamoto, T.: Treatment of severe anterior open bite with skeletal anchorage in adults: Comparison with orthognathic surgery outcomes, Am. J. Orthod. 132:599-605, 2007.
7. Erverdi, N.; Keles, A.; and Nanda, R.: The use of skeletal anchorage in open bite treatment: A cephalometric evaluation, Angle Orthod. 74:381-390, 2004.
8. Sherwood, K.H.; Burch, J.G.; and Thompson, W.J.: Closing anterior open bites by intruding molars with titanium miniplate anchorage, Am. J. Orthod. 122:593-600, 2002.
9. Umemori, M.; Sugawara, J.; Mitani, H.; Nagasaka, H.; and Kawamura, H.: Skeletal anchorage system for open-bite correction, Am. J. Orthod. 115:166-174, 1999.
10. Deguchi, T.; Kurosaka, H.; Oikawa, H.; Kuroda, S.; Takahashi, I.; Yamashiro, T.; and Takano-Yamamoto, T.: Comparison of orthodontic treatment outcomes in adults with skeletal open bite between conventional edgewise treatment and implant-anchored orthodontics, Am. J. Orthod. 139:S60-68, 2011.
11. Fattahi, T.: Aesthetic surgery to augment orthognathic surgery, Oral Maxillofac. Surg. Clin. N. Am. 19:435-447, 2007.
12. Buschang, P.H.; Carrillo, R.; and Rossouw, P.E.: Orthopedic correction of growing hyperdivergent, retrognathic patients with miniscrew implants, J. Oral Maxillofac. Surg. 69:754-762, 2011.
13. Posnick, J.C.; Choi, E.; and Chang, R.P.: Osseous genioplasty in conjunction with bimaxillary orthognathic surgery: A review of 262 consecutive cases, Int. J. Oral Maxillofac. Surg. 45:904-913, 2016.
14. Lindenblatt, N.; van Hulle, A.; Verpaele, A.M.; and Tonnard, P.L.: The role of microfat grafting in facial contouring, Aesth. Surg. J. 35:763-771, 2015.