CASE REPORT

"Surgery-First" Approach with Invisalign Therapy to Correct a Class II Malocclusion and Severe Mandibular Retrognathism

JOY CHANG, BS, DDS, MDS
DEREK STEINBACHER, DMD, MD
RAVINDRA NANDA, BDS, MS, PhD
FLAVIO URIBE, DDS, MDS

For patients with severe skeletal jaw discrepancies, the combination of orthodontics with orthognathic surgery is often the only approach that can both harmonize facial esthetics and restore functional occlusion.[1] Unfortunately, conventional presurgical orthodontics involves a lengthy decompensation period that worsens the patient's facial appearance and exacerbates the malocclusion.[2,3] Many patients pursuing surgical-orthodontic treatment are adults who wish to avoid a deterioration in their profile and facial appearance during presurgical orthodontics.[4]


Dr. Chang


Dr. Steinbacher


Dr. Nanda


Dr. Uribe

Dr. Chang is a former Resident; Dr. Nanda is Professor Emeritus; and Dr. Uribe is an Associate Professor, Postgraduate Program Director, and Charles J. Burstone Endowed Professor, Division of Orthodontics, Department of Craniofacial Sciences, University of Connecticut School of Dental Medicine, Farmington, CT. Dr. Steinbacher is an Associate Professor of Plastic Surgery, Assistant Professor of Pediatrics, and Director of Dental Services, Oral Maxillofacial and Craniofacial Surgery, Yale School of Medicine, New Haven, CT. Dr. Chang is in the private practice of orthodontics in San Jose, CA. Dr. Nanda is also an Associate Editor and Dr. Uribe is a Contributing Editor of the *Journal of Clinical Orthodontics*. E-mail Dr. Uribe at furibe@uchc.edu.

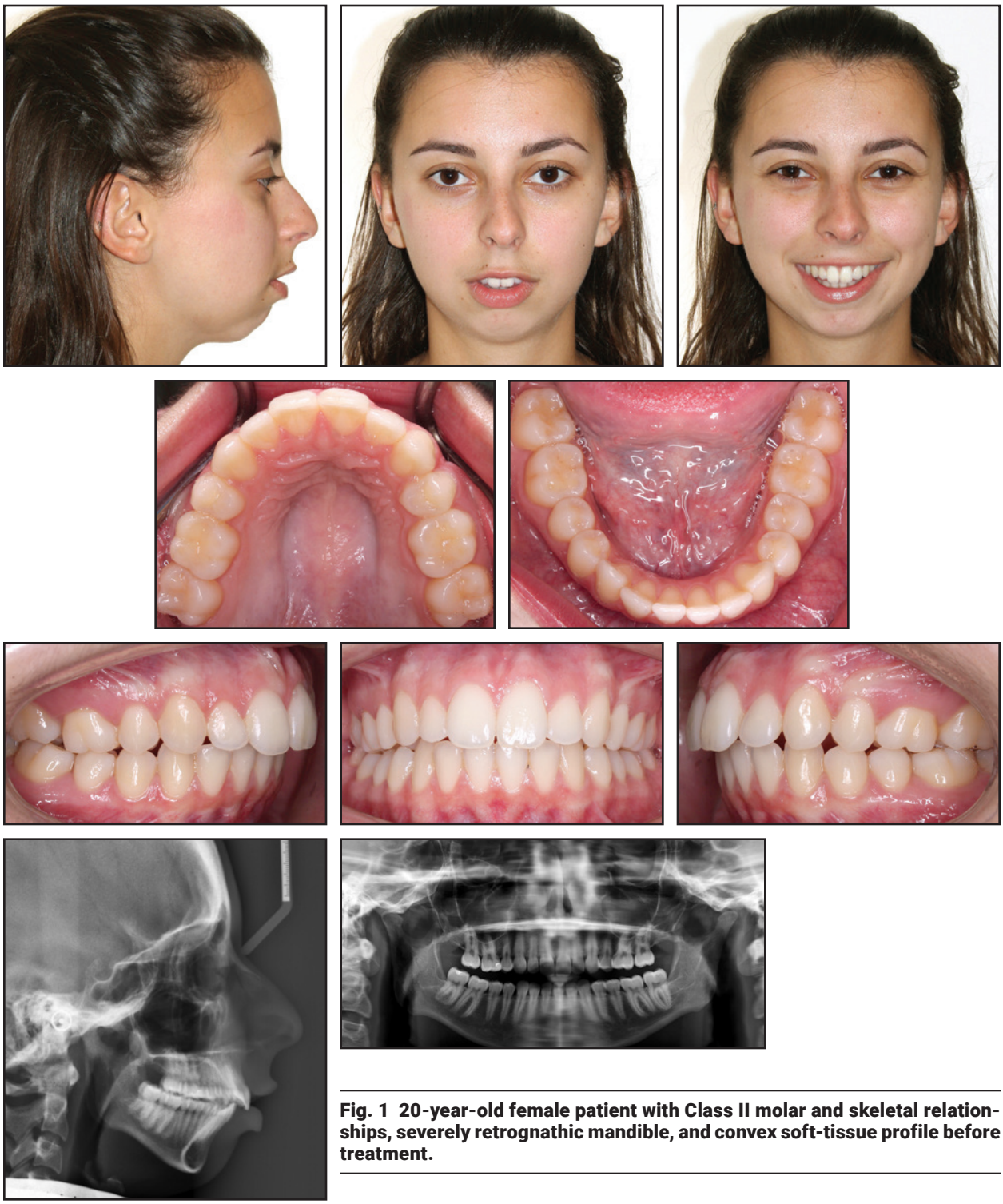

Fig. 1 20-year-old female patient with Class II molar and skeletal relationships, severely retrognathic mandible, and convex soft-tissue profile before treatment.

The "surgery-first" approach, which was introduced to address these disadvantages, has been shown to produce similarly successful outcomes with better patient satisfaction.[5,6] To further improve the esthetics and acceptability of treatment among adult patients, the use of clear aligners such as Invisalign* could be considered for the post-surgical orthodontic phase. ClinCheck* software facilitates the in-depth and accurate surgical planning required for the "surgery-first" approach, allowing the orthodontist and oral surgeon to envision the goals of the entire treatment plan before proceeding.

This case report demonstrates the successful surgical-orthodontic treatment of a patient with a severe Class II skeletal jaw discrepancy using a "surgery-first" approach followed by Invisalign therapy.

Diagnosis and Treatment Plan

A 20-year-old female presented with the chief complaint of mandibular deficiency (Fig. 1). She had received fixed orthodontic treatment involving upper first premolar extractions at age 13 but had declined orthognathic surgery at the time.

Clinical examination found a convex soft-tissue facial profile with a severely retrognathic mandible and retrusive chin, along with 8mm of lip incompetence at rest. The maxillary dental midline was coincident with the facial midline, and the mandibular midline was deviated .5mm to the left of the facial midline. Intraoral photographs and cast analysis showed a full-cusp Class II molar relationship and end-on canine relationship. The overjet was 6mm, and the overbite was 20%. Because of the previous orthodontic treatment, there was no crowding in either arch.

In addition to the upper first premolars, all third molars had been extracted. The patient denied a history of TMD, although asymptomatic clicking of the right TMJ was noted during the extraoral exam. No functional shifts or discrepancy between centric relation and centric occlusion were detected.

The lateral cephalogram indicated a convex skeletal pattern (N-A-Pg = 25.6°) and Class II dental relationship (ANB = 10°; Wits appraisal = +7.4mm). The patient displayed a normal maxillary position (SNA = 80.3°), a retrognathic mandible (SNB = 70.4°), deficient mandibular height (Co-Gn = 93.9mm), and a short mandibular body (Go-Gn = 60mm). The upper incisors were retroclined (U1-SN = 95.2°) and the lower incisors were proclined (L1-SN = 103.9°), resulting in a low interincisal angle (U1-L1 = 116.6°). Vertically, a steep mandibular plane angle (MP-SN = 44.2°) and steep occlusal plane (occlusal plane-SN = 24°) were noted. The soft-tissue profile was significantly convex (G-Sn-Po = 36.7°), and the nasolabial angle (Col-Sn-UL = 113.3°) was excessive. The upper and lower lips were protrusive relative to the E-line (upper lip = 2.8mm; lower lip = 5.3mm) due to the retrognathic chin point.

Polyvinyl siloxane impressions were taken for Invisalign treatment planning prior to surgery. The computer-generated ClinCheck setup displayed the type and placement of attachments. Because surgery was planned, the ClinCheck technician was instructed not to correct the anteroposterior relationship between the maxillary and mandibular arches. Precision cuts in the premolar and molar regions of the mandibular aligners were prescribed to allow elastic wear for vertical seating after surgery. This case required 18 maxillary and 19 mandibular trays.

Materialise ProPlan** was used for virtual treatment planning of a Le Fort I osteotomy, bilateral sagittal split osteotomy, and genioplasty (Fig. 2). A surgical splint would be utilized to correctly position the maxilla and mandible during the orthognathic surgery, but would be removed prior to recovery from anesthesia. The maxillary arch was planned for a 1mm left yaw rotation and posterior disimpaction with rotation around the anterior nasal spine, reducing the occlusal plane angle from 15.4° to 6.6°. An 8mm advancement of the mandible would be followed by a 6mm genioplasty advancement and lengthening. Pogonion would

*Registered trademark of Align Technology, Inc., Santa Clara, CA; www.aligntech.com.
**Registered trademark of Materialise, Plymouth, MI; www.materialise.com.

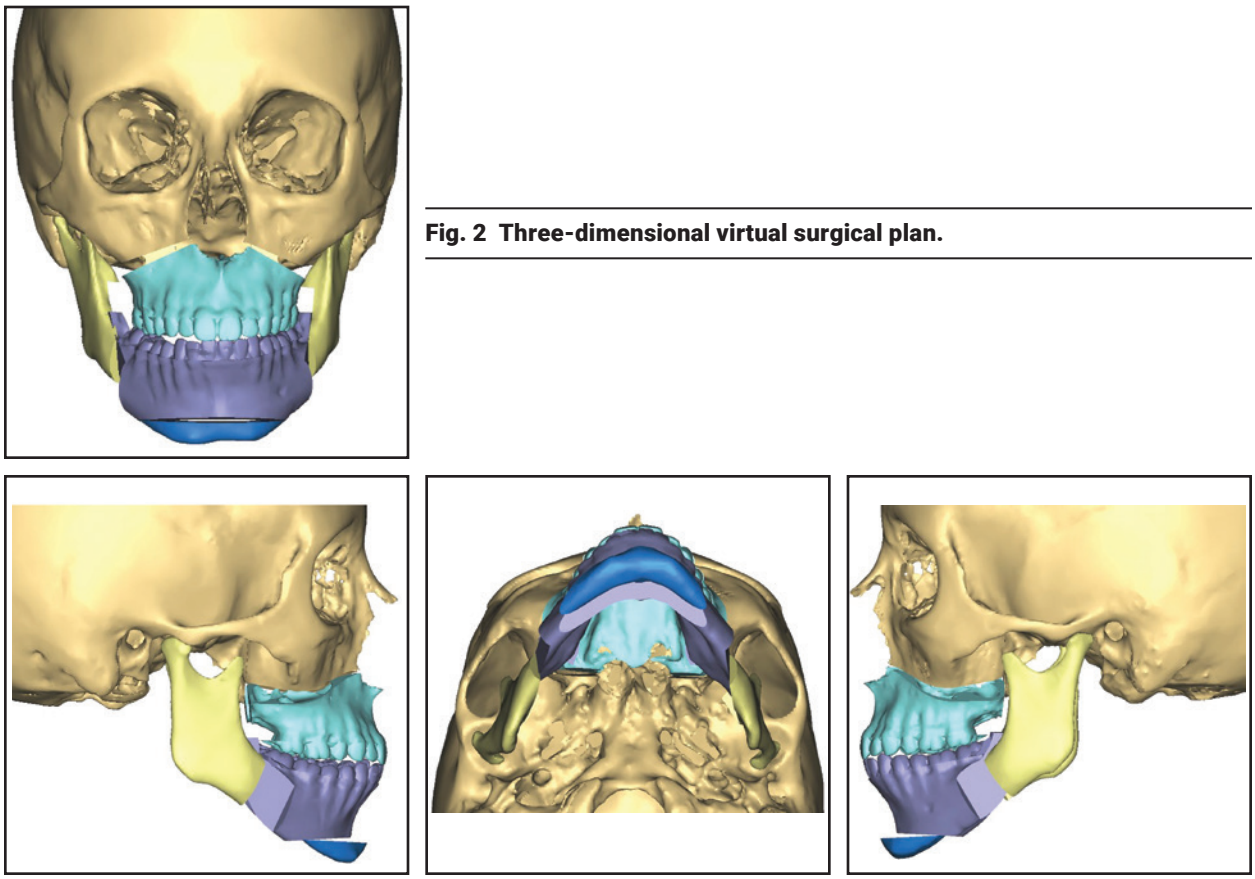

Fig. 2 Three-dimensional virtual surgical plan.

move 20mm anteriorly and 7mm inferiorly as a result of both procedures and the counterclockwise rotation of the maxillomandibular complex. The mandibular advancement was overcorrected to leave the patient with an anterior edge-to-edge relationship and an end-on Class II molar relationship, allowing for some surgical relapse.

The potential for development of a posterior crossbite after mandibular advancement was evaluated in the model surgery. The initial maxillary intermolar width was 42.5mm between the central fossae of the first molars, and the mandibular intermolar width was 44mm between the mesiobuccal cusps of the second molars. This mild discrepancy could be addressed by orthodontic expansion of the maxillary arch, without the need for a segmented maxillary procedure.

Treatment Progress

Because the patient would not be wearing fixed appliances during orthodontic treatment, intermaxillary fixation was supplied by eight temporary anchorage devices (TADs) inserted between the molars and premolars and between the canines and lateral incisors in all quadrants. Class II intermaxillary elastics were worn from the TADs for about six months after surgery to counter any surgical relapse.

Clear-aligner therapy began one month after surgery (Fig. 3). The aligners were changed weekly, and treatment progress was monitored every month for the first three months. After the expected duration of the regional acceleratory phenomenon,[7] the patient started changing aligners every

Fig. 3 One month after surgery, with temporary anchorage devices in place.

two weeks. Because she was attending college in another state and could visit the clinic only every three months, she sent us intraoral photos for remote monitoring. After the patient finished the prescribed series of trays, we bonded a lower fixed retainer and prescribed seating elastics to facilitate extrusion of the lower right posterior occlusion. The TADs were removed 11 months after surgery, when they were no longer needed for elastic anchorage.

During the first six months after surgery, the patient reported an exacerbation of the left TMJ clicking, along with muscular pain. These symptoms resolved with ibuprofen treatment and gentle jaw exercises.

A rhinoplasty was performed to correct a caudal septal deviation 12 months after the orthognathic surgery. The subsequent Invisalign refinement phase required four maxillary trays and 16 mandibular trays.

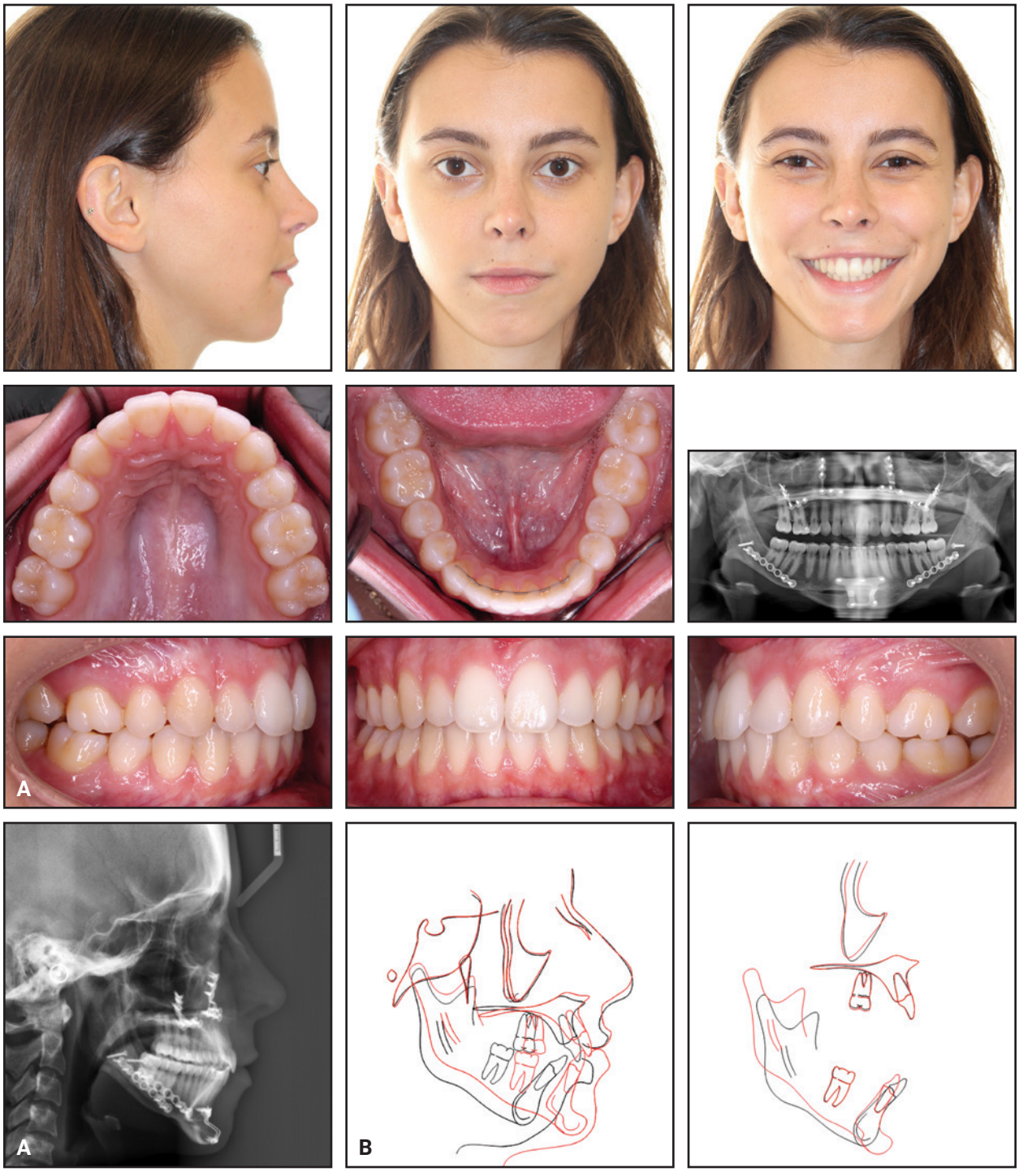

Fig. 4 A. Patient after 19 months of treatment. B. Superimposition of pretreatment (black) and post-treatment (red) cephalometric tracings.

Treatment Results

Total treatment time was 19 months, partly because of the remote monitoring. Post-treatment records showed good dental alignment, with proper seating and functional occlusion (Fig. 4). The soft-tissue profile was straight, and the mandibular retrognathia and lip incompetence were corrected. A final panoramic x-ray indicated root parallelism, without significant root shortening or development of other pathologies. The patient reported resolution of the left TMJ clicking and no further signs or symptoms of TMD. Cephalometric superimposition confirmed the significant mandibular advancement resulting from the osteotomies and rotation of the maxillomandibular complex. The patient was satisfied with the final esthetic outcome and resolution of her complaint.

Discussion

This case demonstrates a novel "surgery-first" approach combined with Invisalign to treat a severe skeletal Class II malocclusion caused by mandibular retrognathism. We selected this plan both to address the chief complaint of mandibular deficiency earlier in treatment and to accommodate the patient's specific wish to receive clear-aligner therapy after she had worn fixed appliances as a teenager. The patient was well suited to this approach because of her good initial alignment and her lack of major transverse discrepancies and occlusal interferences when the models were advanced to Class I canine and Class II molar relationships.

Accurate prediction of the final outcome is integral to the success of the "surgery-first" approach. Invisalign's ClinCheck system facilitates precise development of virtual treatment objectives by illustrating the anticipated final occlusion. In our case, we could take preoperative Invisalign impressions because minimal dental changes were expected from the surgery. During the postsurgical phase, the addition of elastics to the clear aligners helped correct the anteroposterior relationship of the maxillary and mandibular arches.

The patient's maxillomandibular complex was surgically rotated 8° counterclockwise to alleviate the steepness of her occlusal plane and to increase her chin projection, thus improving facial harmony. Such surgical alteration has been shown to be stable when rigid fixation is used.[8-13] In the case shown here, surgical stability was enhanced with the use of Class II elastics to reduce the load potential, allow soft-tissue relaxation, and counter any stretching of the muscles of mastication.[12] Incision into the pterygoid masseteric sling could further improve surgical stability by readaptation of the muscles during the healing process.[9] Several authors have reported stable surgical results in patients with healthy TMJs.[9,12,13] The increase in loading of the TMJs caused by the counterclockwise rotation reaches equilibrium within a few months, as the joints adapt to their new positions.[9] Our patient's symptoms of TMJ clicking were transient and were resolved by the end of treatment.

One disadvantage of this approach is that the success of Invisalign treatment largely depends on patient compliance. Because patients who undergo orthognathic surgery may experience burnout after surgery addresses their main complaints, it might be more challenging to complete orthodontic treatment with clear aligners. Despite some lack of compliance toward the end of treatment, however, our patient still achieved a pleasing and esthetic outcome. This case demonstrates that Invisalign can be effectively used in conjunction with orthognathic surgery for patients who request more esthetic treatment options.

REFERENCES

1. Grubb, J. and Evans, C.: Orthodontic management of dentofacial skeletal deformities, Clin. Plast. Surg. 34:403-415, 2007.
2. O'Brien, K.; Wright, J.; Conboy, F.; Appelbe, P.; Bearn, D.; Caldwell, S.; Harrison, J.; Hussain, J.; Lewis, D.; Littlewood, S.; Mandall, N.; Morris, T.; Murray, A.; Oskouei, M.; Rudge, S.; Sandler, J.; Thiruvenkatachari, B.; Walsh, T.; and Turbill, E.: Prospective, multi-center study of the effectiveness of orthodontic/orthognathic surgery care in the United Kingdom, Am. J. Orthod. 135:709-714, 2009.
3. Luther, F.; Morris, D.O.; and Hart, C.: Orthodontic preparation for orthognathic surgery: How long does it take and why? A retrospective study, Br. J. Oral Maxillofac. Surg. 41:401-406, 2003.
4. Pelo, S.; Gasparini, G.; Garagiola, U.; Cordaro, M.; Di Nardo, F.; Staderini, E.; Patini, R.; de Angelis, P.; D'Amato, G.;

Saponaro, G.; and Moro, A.: Surgery-first orthognathic approach vs. traditional orthognathic approach: Oral health-related quality of life assessed with 2 questionnaires, Am. J. Orthod. 152:250-254, 2017.
5. Liou, E.J.; Chen, P.H.; Wang, Y.C.; Yu, C.C.; Huang, C.S.; and Chen, Y.R.: Surgery-first accelerated orthognathic surgery: Orthodontic guidelines and setup for model surgery, J. Oral Maxillofac. Surg. 69:771-780, 2011.
6. Yang, L.; Xiao, Y.D.; Liang, Y.J.; Wang, X.; Li, J.Y.; and Liao, G.Q.: Does the surgery-first approach produce better outcomes in orthognathic surgery? A systematic review and meta-analysis, J. Oral Maxillofac. Surg. 75:2422-2429, 2017.
7. Liou, E.J.; Chen, P.H.; Wang, Y.C.; Yu, C.C.; Huang, C.S.; and Chen, Y.R.: Surgery-first accelerated orthognathic surgery: Postoperative rapid orthodontic tooth movement, J. Oral Maxillofac. Surg. 69:781-785, 2011.
8. Chemello, P.D.; Wolford, L.M.; and Buschang, P.H.: Occlusal plane alteration in orthognathic surgery, Part II: Long-term stability of results, Am. J. Orthod. 106:434-440, 1994.
9. Coleta, K.E.; Wolford, L.M.; Gonçalves, J.R.; Pinto Ados, S.; Cassano, D.S.; and Gonçalves, D.G.: Maxillo-mandibular counter-clockwise rotation and mandibular advancement with TMJ Concepts total joint prostheses, Part II: Airway changes and stability, Int. J. Oral Maxillofac. Surg. 38:228-235, 2009.
10. Esteves, L.S.; Castro, V.; Prado, R.; de Moraes e Silva, C.Á.; do Prado, C.J.; and Trindade Neto, A.I.: Assessment of skeletal stability after counterclockwise rotation of the maxillomandibular complex in patients with long-face pattern subjected to orthognathic surgery, J. Craniofac. Surg. 25:432-436, 2014.
11. Reyneke, J.P.; Bryant, R.S.; Suuronen, R.; and Becker, P.J.: Postoperative skeletal stability following clockwise and counter-clockwise rotation of the maxillomandibular complex compared to conventional orthognathic treatment, Br. J. Oral Maxillofac. Surg. 45:56-64, 2007.
12. Sonego, C.L.; Bobrowski, Â.N.; Chagas, O.L. Jr.; and Torriani, M.A.: Aesthetic and functional implications following rotation of the maxillomandibular complex in orthognathic surgery: A systematic review, Int. J. Oral Maxillofac. Surg. 43:40-45, 2014.
13. Wolford, L.M.; Chemello, P.D.; and Hilliard, F.: Occlusal plane alteration in orthognathic surgery, Part I: Effects on function and esthetics, Am. J. Orthod. 106:304-316, 1994.